



# USE OF FEMORAL HEAD ALLOGRAFTS IN THE TREATMENT OF NONSPECIFIC SPONDYLODISCITIS OF THE THORACIC AND LUMBAR SPINE

V.K. Shapovalov<sup>1,2</sup>, I.V. Basankin<sup>1,2</sup>, A.A. Afaunov<sup>1,2</sup>, I.V. Gilevich<sup>1</sup>, A.A. Giulzatyan<sup>1</sup>, N.V. Tushkanova<sup>2</sup>

<sup>1</sup>Research Institute – Krasnodar Regional Clinical Hospital No. 1

n.a. Prof. S.V. Ochapovsky, Krasnodar, Russia;

<sup>2</sup>Kuban State Medical University, Krasnodar, Russia

**Objective.** To analyze clinical and radiological results of two-stage surgical treatment of nonspecific spondylodiscitis with anterior debridement of the infection site and corporodesis using a container-type titanium implant filled with allograft material obtained from the femoral heads during primary endoprosthetics.

**Material and Methods.** A retrospective single-center study initially included 31 patients with spinal infection. After exclusion of two cases of tuberculous spondylodiscitis, the final study cohort consisted of 29 patients (13 men, 16 women; mean age – 64.7 years) with nonspecific spondylodiscitis of the thoracic and lumbar spine who underwent surgery between 2017 and 2022. All patients underwent a two-stage surgical intervention: anterior debridement of the lesion with placement of a titanium cylindrical cage filled with allograft material, followed by posterior transpedicular fixation. The minimum follow-up period was 18 months (mean 27.7 months). Clinical parameters (VAS, Frankel scale, MacNab scale), laboratory inflammatory markers, and the quality of bone fusion according to the Tan classification were assessed.

**Results.** The mean preoperative VAS pain score was 7.9; it decreased to 4.5 at discharge and to 1.9 at 18 months postoperatively ( $p < 0.001$ ). Neurological improvement was observed in 14 (66.7%) of 21 patients with preoperative deficits, and complete regression in 8 (38.1%) patients. Radiographic assessment showed Grade I–II bone fusion according to Tan in 93.5% of patients. No cases of pseudoarthrosis or implant migration were observed. Excellent and good functional outcomes according to the MacNab scale were achieved in 83.8% of patients. Early infectious complications in the anterior approach area occurred in 9.7% of cases and were successfully managed with staged surgical treatment and VAC therapy. No generalized infection, implant removal, or deaths were recorded.

**Conclusion.** The use of allogeneic femoral head bone grafting in the treatment of nonspecific spondylodiscitis as part of a two-stage surgical approach provides reliable spinal segment stabilization, solid bone fusion, and significant clinical improvement. This method has demonstrated high efficacy and safety, and represents a valuable alternative to autografts, particularly in debilitated patients.

**Key Words:** spondylodiscitis; allogeneic bone grafting; anterior debridement; corporodesis; transpedicular fixation; bone fusion; spinal infection.

Please cite this paper as: Shapovalov VK, Basankin IV, Afaunov AA, Gilevich IV, Giulzatyan AA, Tushkanova NV. Use of femoral head allografts in the treatment of nonspecific spondylodiscitis of the thoracic and lumbar spine. *Russian Journal of Spine Surgery (Khirurgiya Pozvonochnika)*. 2026;23(1):72–81. In Russian. DOI: <http://dx.doi.org/10.14531/ss2026.1.72-81>

Infectious lesions of the spine have been known since ancient times, evidence of diseases of this group has been revealed in the study of archaeological remains. However, despite the centuries-old history, spinal infections remain an urgent clinical problem due to difficulties in early diagnosis, a variety of clinical manifestations and a high risk of complications with untimely treatment [1–3]. The most common form is non-specific spondylodiscitis, which arises predominantly due to hematogenous spread of infection in immunocompromised patients or after

diagnostic or surgical interventions [4–6]. The average time for establishing a diagnosis ranges from 2 to 4 months, which is due to the non-specificity of initial symptoms and the absence of typical radiological changes at an early stage [7–9].

The frequency of non-specific spondylodiscitis ranges from 2 to 4 cases per 100,000 population per year, with a sharp increase in incidence in the age group older than 70 years. Men are prone to this infection approximately 5 times more often than women [10, 11]. Patients with immunodeficiency conditions, including HIV, diabetes mellitus,

oncological diseases and drug addiction, have an increased risk of developing infectious lesions of the spine. Clinical manifestations of the disease on average precede radiological signs by 1–2 months, which complicates early diagnosis and often leads to erroneous treatment for degenerative spinal diseases [7, 11]. MRI remains the method of choice for early detection of spondylodiscitis, however its limited availability in a number of clinical situations contributes to late diagnosis and increases the probability of the formation of abscesses, pronounced destruction of vertebrae and development of neurological deficit.

In the presence of significant bone destruction, mechanical instability or neurological disorders, surgical treatment becomes an essential component of therapy, combining radical debridement of the infectious focus with the restoration of the supporting function of the spine [12, 13]. At the same time, the optimal choice of transplantation material under conditions of an active inflammatory process remains a subject of discussion [1].

Despite the presence of historically accumulated experience in the application of bone grafting in infectious lesions of the spine, in modern clinical practice the urgent problem of choosing optimal material for the reconstruction of the anterior supporting column under conditions of an active infectious process remains. Autograft, traditionally considered as the preferred material, has a number of objective limitations: its harvesting increases the traumatization of the intervention and its duration, is accompanied by a risk of donor site complications, and in a subset of patients (elderly, somatically burdened, with a pronounced inflammatory process) is technically difficult or clinically inappropriate.

Current clinical guidelines of the Russian Federation “Inflammatory lesions of the spine” (2024) permit the use of a combination of posterior instrumental fixation and anterior reconstruction using non-biological supporting implants (including titanium cages) and bone material, however they do not regulate a specific type of biological filler [14]. In this regard, the search for accessible, biologically safe and clinically effective alternatives to autograft for filling titanium cages in the surgical treatment of non-specific spondylodiscitis presents an urgent scientific and practical task.

In modern conditions, surgical tactics for non-specific osteomyelitis of the spine includes radical debridement of the focus, restoration of the anterior supporting column and circumferential (360°) stabilization, ensuring early mobilization of the patient [12, 15]. At the same time, the remodeling of the bone graft under conditions of past infection is a long biological process, which is con-

firmed by both classic and modern clinical observations [16, 17]. Essential significance in this context is acquired not only by the choice of surgical tactics, but also by the properties of the used transplantation material, on which the rates of remodeling, the stability of reconstruction and the clinical outcome largely depend. Clinical limitations to the application of autograft, including increased surgical traumatization and the risk of complications from the donor site, are particularly significant in patients with severe somatic background and an active inflammatory process [18]. In this regard, as an alternative, allogeneic materials that have undergone thermal disinfection and cryopreservation are considered, which ensures a high degree of biological safety while preserving osteoconductive properties [15, 17]. World-wide literature sources offer only isolated works concerning the use of allogeneic grafts in infectious lesions of the spine, predominantly in the form of lyophilized materials [19–21]. At the same time, information on systematic clinical series of the application of allogeneic crumb from femoral heads within a titanium cage for active non-specific spondylodiscitis is absent in the literature.

Objective of the study was an analysis of clinical and radiological results of two-stage surgical treatment of non-specific spondylodiscitis with the execution of anterior debridement of the infection focus and corporodesis with a titanium container-type implant filled with allograft material obtained from femoral heads during primary endoprosthesis replacement.

### Material and Methods

In 2017–2022 on the basis of the Research Institute – Regional Clinical Hospital No. 1, 31 patients with an infectious lesion of the spine were treated with the considered two-stage surgical method. After verification of the pathogen, two cases of tuberculous spondylodiscitis were excluded from the analysis in accordance with the inclusion criteria. Thus, the final studied sample amounted to 29 patients with

confirmed non-specific spondylodiscitis of the thoracic and lumbar spine. All patients underwent a two-stage surgical intervention using allogeneic bone material, which represents femoral heads resected during primary hip joint endoprosthesis replacement, harvested in accordance with legislative acts on organ and tissue donation. Processing of bone tissue was carried out using the Lobator SD-2 apparatus (Germany). The Lobator SD-2 system implements a standardized technology of thermal disinfection, ensuring heating of the bone graft to an internal temperature of no less than 82.5°C with subsequent maintenance of the regimen and controlled cooling. The full processing cycle takes 94 minutes and is fully automated, excluding the possibility of changes to temperature-time parameters by the user. Before the start of processing, the bones were placed in a hermetic sterile container with a transfer solution. The process included three successive phases: heating, maintaining the temperature plateau and cooling. Upon completion of the cycle, a protocol of processing was automatically generated, confirming the correspondence to the temperature regimen and sterility. The method is aimed at inactivating viral (HIV-1/2, HTLV, HBV, HCV, CMV), bacterial (aerobic and anaerobic) and fungal infections. At the same time, the mechanical and biological properties of the bone tissue are preserved. After thermal processing, the container with the transplant was stored in a freezer at a temperature of –40°C in a biobank. Before use, the bone material was thawed using the defrosting program of the Lobator SD-2 system and transferred to the operating room for use.

The localization of the infectious process varied from T5 to S1. The most frequently affected levels were T8–T10 vertebrae and the lower lumbar segments (L4–L5, L5–S1). The distribution of patients by lesion levels is given in Table 1.

Additionally, a morphological assessment of the lesion was performed according to CT data. The degree of bone destruction, the magnitude of ver-

tebral translation and the severity of local kyphotic deformity were analyzed. The distribution of patients by CT characteristics is given in Table 2.

**Inclusion criteria for the study:** presence of clinically and instrumentally confirmed non-specific spondylodiscitis, performance of two-stage surgical intervention, use of a titanium cylindrical cage filled with allograft material, period of postoperative observation of no less than 18 months.

**Non-inclusion criteria:** refusal of the patient from surgical treatment, application of other treatment methods.

**Exclusion criteria:** gross violation of the regimen of postoperative rehabilitation, absence of data from control examinations, loss of connection with the patient during observation.

Indications for surgical treatment were pronounced destruction of the vertebral body of more than 50%, translation of the vertebra of more than 5 mm, kyphotic deformity of the segment of more than 25°, presence of neurological deficit (Frankel B–D), as well as lack of effect from conservative antibacterial therapy for four weeks and more with signs of progression of the pathological process [22].

Surgical treatment was carried out according to a unified protocol developed and implemented in the clinic since 2016. All interventions were performed by 2 leading spine surgeons with more than 10 years of experience. The first stage included debridement of the infection focus via an anterior approach (transthoracic – for thoracic localization, and retroperitoneal – for lumbar), removal of non-viable tissues and installation of a titanium cage filled with allograft crumb under conditions of retraction. The second stage (after 5–7 days) included conducting transpedicular fixation from a posterior approach using minimally invasive techniques.

Before surgery, all patients underwent a comprehensive clinical, laboratory and instrumental examination, including MRI, CT, ultrasound examination of the veins of the lower extremities, echocardiography, esophagogastroduodenoscopy, as well as consultations of a therapist, cardi-

ologist, endocrinologist and neurologist. Neurological status was assessed according to the Frankel scale, pain syndrome – according to the VAS, the quality of bone fusion – according to the Tan classification based on control CT study, performed at 3, 6, 12 and 18 months after surgery. Subjective evaluation of the results was carried out according to the MacNab scale at the last visit. The dynamics of inflammatory laboratory indicators were evaluated comprehensively, which included the level of C-reactive protein, erythrocyte sedimentation rate and absolute leukocyte count. Determination of the concentration of procalcitonin was not performed routinely, but strictly according to clinical indications: in cases where there was a suspicion of a systemic inflammatory reaction or the development of sepsis. Such situations included persistent fever above 38.5° C lasting more than 24–48 hours against the background of antibacterial therapy, an increase in the level of C-reactive protein after a stabilization period or the absence of its decrease at initially high values, the appearance of signs of a systemic inflammatory reaction (tachycardia of more than 100–110 beats/minute, tachypnea of more than 22–24 per minute, episodes of arterial hypotension), as well as clinical suspicion of infection generalization, including pronounced intoxication, chills, need for infusion therapy or the presence of local deterioration (intensification of pain syndrome, increase in discharge through the drain, signs of phlegmon). In the indicated situations, procalcitonin was used as an additional marker of systemic inflammatory reaction, allowing assessment of the probability of a septic process; in the absence of clinical signs of infection generalization, its determination was not carried out. Control laboratory investigations were performed serially at all stages of treatment, including the postoperative period. All patients from the moment of hospitalization underwent empirical broad-spectrum antibacterial therapy with vancomycin (1 g I.V. 2 times a day) and ceftriaxone (2 g I.V. 2 times a day). After obtaining the results of microbiological culture, antibiotic therapy was

adjusted taking into account sensitivity. The duration of antibacterial treatment was no less than eight weeks, of which no less than four – in inpatient conditions [22].

Treatment of patients was carried out in 2017–2022 within standard clinical practice in accordance with the regulatory documents valid at that time. The protocol of retrospective analysis of clinical data was approved by the local ethics committee of the institution (protocol No. 154 dated February 16, 2023). The work was performed in accordance with the ethical principles of the Declaration of Helsinki of the World Medical Association (revision of the year 2024). Procurement, processing and clinical application of allogeneic bone material were carried out in a subdivision of the clinic having a bone bank, on the basis of a valid license for the provision of medical services for the procurement and transplantation of organs and tissues. All patients gave voluntary informed consent for the use of clinical data and biological material for scientific purposes.

Statistical data processing was carried out using the software package Statistical Package for the Social Sciences Statistics version 23.0. For the analysis of differences in quantitative continuous variables (for example, Visual Analogue Scale indicators, erythrocyte sedimentation rate, C-reactive protein), the non-parametric Wilcoxon test for related samples was used. For categorical variables (Frankel, Tan, MacNab scales), the chi-square criterion ( $\chi^2$ ) or Fisher's exact test was

**Table 1**

Distribution of patients by levels of spinal lesion ( $n = 29$ )

Level	Patients, $n$	Proportion, %
T5–T7	2	6.9
T8–T10	7	24.1
T11–T12	3	10.3
L1–L2	4	13.8
L3–L4	3	10.3
L4–L5	7	24.1
L5–S1	3	10.3

Table 2

Morphological characteristics of the lesion according to CT data ( $n = 29$ )

Level	Patients, $n$	Proportion, %
Destruction less than 30% of the vertebral body	5	17.2
Destruction 30–50%	11	37.9
Destruction more than 50% of the body	13	44.9
Translation of the vertebra more than 5 mm	6	20.7
Kyphotic deformity more than 25°	7	24.1

applied at expected frequencies of less than 5. Differences between the studied parameters are classified as statistically significant at a critical level of  $p \leq 0.05$ , which corresponds to generally accepted criteria in clinical science. Main quantitative indicators are presented in the form of mean value  $\pm$  standard deviation with the calculation of 95% Confidence Intervals. Fusion according to the Tan classification was assessed by 2 independent surgeons who did not participate in the surgical treatment; in case of discrepancies, the decision was made on the basis of consensus.

## Results

The study included 29 patients. Lethal outcomes in the postoperative period and during observation were absent. All patients were followed up at established times. The average age of the patients – 64.7 years (95% CI: 60.1–69.2); 13 (44.8%) men and 16 (55.2%) women. The average follow-up time – 27.7 months (95% CI: 25.1–30.2), range – from 18.2 to 37.5 months.

The pain syndrome according to the VAS demonstrated pronounced positive dynamics. Before surgery, the average pain level was 7.9 points (95% CI: 7.4–8.3). At discharge, this indicator decreased to 4.5 points (95% CI: 4.2–4.9;  $p < 0.01$ ), and at the last visit – to 1.9 points (95% CI: 1.7–2.0;  $p < 0.001$ ) compared to the baseline.

Neurological deficit according to the Frankel scale before surgery was noted in 19 (65.5%) patients: in 4 (21.1%) – category B, in 8 (42.1%) – category C, in 7 (36.8%) – category D. After treatment, an improvement in neurological status

was observed in 13 (68.4%) patients (44.8% of the total sample), including in 7 (36.8%) patients (24.1% of the total sample) complete regression of the deficit (Frankel E) was achieved. Not a single case of deterioration of neurological status was recorded. Changes according to the Frankel scale reached statistical significance ( $p = 0.001$ ).

Radiological assessment of bone fusion according to the Tan classification after 18 months showed the following distribution: Grade I – 22 (75.9%) patients, Grade II – 5 (17.2%), Grade III – 2 (6.9%), Grade IV – not revealed (0%). The reliability of fixation was assessed as satisfactory or good in 27 (93.1%) patients. Cases of pseudarthrosis, migration or fracture of implants were not noted.

Subjective assessment of functional outcome according to the MacNab scale after 18 months demonstrated a predominance of positive results: an excellent result was registered in 5 (17.2%) patients, good – in 19 (65.5%), satisfactory – in 5 (17.2%). Unsatisfactory outcomes were not revealed.

Microbiological examination allowed identifying the pathogen in 23 (79.3%) out of 29 patients [23]. Most often *Staphylococcus aureus* was identified – in 8 patients (including 4 cases of methicillin-resistant strain, MRSA). *Pseudomonas aeruginosa* was revealed in 2 patients, in another case – in combination with *Enterococcus faecalis*. *Klebsiella pneumoniae*, *Enterococcus faecalis* (in monoculture) and *Escherichia coli* were revealed in 2 cases each. *Streptococcus viridans*, *Acinetobacter baumannii* and coagulase-negative *Staphylococcus epidermidis* – in one case each. In 6 (20.7%) patients the cultures were negative.

The dynamics of laboratory indicators reflected the successful arrest of the inflammatory process. The average time for normalization of the C-reactive protein level was 4.7 weeks (95% CI: 4.2–5.2), and a 50% decrease in the erythrocyte sedimentation rate level was achieved on average after 3.3 weeks (95% CI: 2.9–3.8) from the start of antibacterial therapy. Normalization of the leukocyte formula occurred on average within 2.1 weeks (95% CI: 1.7–2.4). A significant increase in procalcitonin was noted only in a limited number of patients with a more severe course, it was used predominantly as an additional criterion for systemic inflammatory reaction, without separate quantitative analysis in the overall cohort.

The average duration of the operation was 4 hours 26 minutes (266 minutes; 95% CI: 242–290), including 180 minutes for the anterior stage and 86 minutes for the posterior fixation stage. The duration of interventions varied from 3 hours 38 minutes to 7 hours 12 minutes.

The average intraoperative blood loss was 850 mL (95% CI: 740–960 mL), ranging from 350 to 1100 mL. The average hospital stay was 6.5 weeks (95% CI: 5.8–7.1), range – from 3 to 9 weeks. Early infectious complications in the area of operative intervention were registered in 3 (10.3%) patients. In all cases, suppuration of the retroperitoneal approach wound was noted; patients underwent revision, debridement and Vacuum-Assisted Closure therapy. Repeated interventions, removal of implants or generalization of infection were not observed.

Clinical examples are shown in Fig. 1, 2.

## Discussion

The choice of optimal transplantation material in the surgical treatment of non-specific spondylodiscitis remains a subject of active clinical and scientific discussions. Autografts, possessing pronounced osteogenic, osteoconductive and osteoinductive properties, are traditionally considered as the most preferred option for restoring bone defects of the spine [1]. However, their use is associated with the necessity of harvesting bone tissue from

a donor zone, which is accompanied by additional surgical trauma, an increase in the duration of the operation, the risk of infectious complications and chronic pain syndrome in the donor area [18]. In this regard, allografts represent a clinically significant alternative. Thanks to modern harvesting methods, including thermal disinfection and cryopreservation, the level of infectious and immunological threat is minimized.

Historically, the application of allogeneic bone tissue in spinal diseases counts more than 70 years, and in Russian vertebrology the conceptual foundations of its use were formed predominantly in the 1960s–1990s and relied on a significant array of experimental and clinical studies. In the works of E.N. Bellendir [24] and E.N. Bellendir and I.U. Salmogambetov [25], the possibilities of interbody reconstruction with the use of allobone grafts in tuberculous and non-specific lesions of the spine were substantiated. Experimental studies by I.P. Boyarkina [26] showed the capability of an allo-transplant for vascularization and reparative remodeling even under conditions of active infectious inflammation. Clinical results of using allogeneic bone in the reconstruction of the anterior supporting column of the spine were summarized in the works of V.N. Guseva and A.E. Garbuz [27], where the formation of a bone block in 60–68% of patients was reported provided compliance with a prolonged bed or unloading rest, exceeding 6 months. A significant contribution to the development of ideas about allobone grafting was also made by the studies of Ya.L. Tsivyan et al. [28], V.K. Letina and I.P. Ardashev [29], which confirmed the fundamental clinical feasibility of this approach in inflammatory and destructive lesions of the spinal column.

At the same time, the surgical techniques of that period fundamentally differed from modern ones: reconstruction was carried out predominantly with massive structural bone blocks without the use of metal constructs, which required prolonged bed immobilization and external fixation of patients, limited early verticalization and was accompanied by the risk of secondary deformities and insta-

bility. In this context, the accumulated data represent an important historical foundation, however, they significantly differ in biomechanics and methodology from modern spinal reconstruction technologies. The introduction into clinical practice of transpedicular fixation systems, titanium cages and the concept of circumferential (360°) stabilization allowed forming modern surgical tactics for treating infectious lesions of the spine, combining radical debridement of the focus, restoration of the anterior supporting column and early mobilization of patients [12, 15]. At the same time, the structural remodeling of the bone graft under conditions of transferred infection remains a long biological process, usually lasting 1.5–2 years, which is confirmed by both classic studies and modern clinical observations [16, 17].

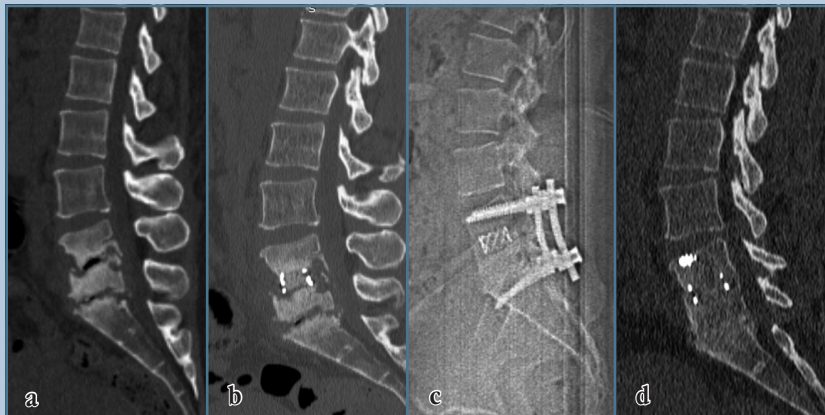
When comparing allogeneic material with autogenous bone, it is necessary to consider not only biological, but also clinico-anatomical aspects. In approaches to the lower thoracic spine, obtaining a limited volume of autogenous bone material from the resected rib fragment is possible. However, this volume, as a rule, is insufficient for the full filling of a titanium cage in severe destruction of vertebral bodies, multi-level lesion or the need for reconstruction of a significant bone defect. In addition, the structure of cortical rib bone significantly differs from cancellous bone in its osteoconductive properties. In lesions of the thoracic and thoracolumbar spine, where access to the vertebral bodies is carried out without rib resection, the deficit of autogenous bone material becomes even more obvious, and additional harvesting of bone requires a separate donor intervention and is accompanied by an increase in the traumatization of the operation.

The use of allograft material obtained from femoral heads during primary hip replacement possesses a number of clinically significant advantages. It is important to emphasize that the source of allograft material in the present work are femoral heads removed during primary hip replacement. This material belongs to tissues of intravital donation

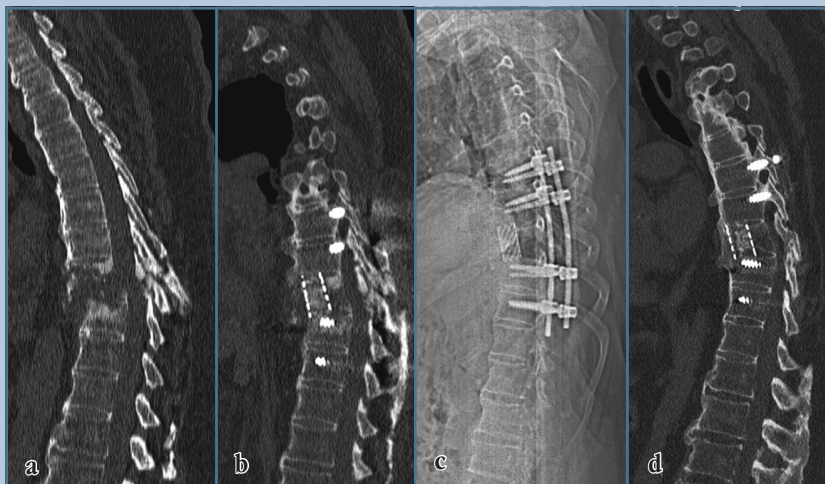
and is obtained within the framework of a standard operative intervention, which allows ensuring a documentarily confirmed informed voluntary consent of the patient for harvesting, processing and clinical application of the graft. Taking into account the high frequency of primary hip replacement, such a donor base forms a potentially unlimited and reproducible resource of bone material, which in routine practice in many institutions otherwise is not used and is subject to disposal. The cancellous structure of the femoral head provides pronounced osteoconductive properties of the transplant and good adaptation to filling titanium cages. The homogeneity of microarchitecture, the reproducibility of volume and the stable quality of the material allow forming a predictable biological environment for reparative remodeling in the corporodesis zone.

Taken together, these features allow considering allograft material from femoral heads as a clinically justified alternative to autogenous bone in the reconstruction of the anterior supporting column of the spine, especially in multi-level lesions, pronounced destruction of vertebral bodies and localization of the process in the lumbar region. In the present study, the application of allogeneic material from femoral heads inside a titanium cage ensured the formation of a satisfactory interbody block (Grades I–II according to Tan) in 93.5% of patients, which is comparable to the results of applying autogenous bone. According to McHenry et al. [30], interbody fusion was achieved in 92–94% of observations, and in the study by Hadjipavlou et al. [31] – in 90–95%. Thus, the proposed method demonstrates equivalent effectiveness without risks associated with harvesting autograft, and exceeds historical series of Russian observations, in which prolonged immobilization was required.

Comparison with synthetic osteoconductive materials ( $\beta$ -tricalcium phosphate, hydroxyapatite, calcium sulfate composites, PerOssal) is difficult due to the extremely limited volume of published data. Available works either include small series or describe single clinical cases, and the obtained results

**Fig. 1**

Patient R., aged 59, with non-specific spondylodiscitis of the L4–L5–S1 vertebrae: **a** – CT before surgery, destruction of the bodies of L4–S1 vertebrae; **b** – CT after surgery (ventral corporodesis with a cage with allograft); **c** – radiography after the second stage of surgery, control of the position of implants; **d** – CT 18 months after surgery, high-quality bone block (Grade I according to Tan)

**Fig. 2**

Patient N., aged 73, with non-specific spondylodiscitis of the T8–T10 vertebrae: **a** – CT before surgery, destruction of the bodies of the T8–T10 vertebrae; **b** – CT after surgery (posterior fixation and anterior corporodesis with a cage with allograft); **c** – radiography after surgery, control of the position of implants; **d** – CT 18 months after surgery, high-quality bone block (Grade I according to Tan)

are characterized predominantly by peripheral remodeling without the formation of a full-fledged interbody bone block. In the study by von Stechow and Rauschmann (19 patients), only marginal ossification was noted [32]. Separate reports describe the application of

antibiotic-loaded calcium sulfate materials in spondylodiscitis, however the volume of clinical data remains limited [33].  $\beta$ -TCP is described in only one clinical observation [34]. Due to their fragmentation, synthetic materials cannot serve as a valid group for

direct comparison with an active infectious process.

PMMA-cement provides high primary mechanical stability, but does not possess biological integration. In the study by Deml et al. (73 patients), satisfactory load-bearing capacity of the construct was achieved, however, a bone block in the reconstruction zone was not formed [35]. Consequently, cement reconstruction is not a biological analogue and is inferior to methods providing a full-fledged osseointegrative process.

The clinical and radiological results obtained by us confirm the reliability of the restored anterior support and stability of the interbody construct. The absence of infection recurrences, serious complications and the favorable dynamics of inflammatory markers indicate the safety of using allograft material under conditions of an active infectious process [19, 21]. Long-term (18-month) follow-up and a high frequency of interbody fusion allow making a preliminary conclusion about the high clinical efficacy and biological viability of the proposed method. Perspectives for further research include multicenter comparative projects, direct comparison with autogenous bone, synthetic osteoconductive materials and cement reconstruction, as well as the development of biologically active modifications of the allotransplant with osteoinductive factors, including BMP-2.

*Limitations of the study.* The limitations of the present study are its retrospective design, a relatively small sample size and the absence of a control group. In addition, the potential heterogeneity of the quality of the used allograft material should be taken into account. Femoral heads removed during endoprosthesis replacement can be characterized by varying of dystrophic changes, osteoporosis or, conversely, subchondral sclerosis and “corticalization” of cancellous bone. Theoretically, this can condition differences in the structure of the transplant and, correspondingly, in the severity of its osteoconductive properties, which is potentially capable of influencing the processes of osseointegration. Within the framework of the present study, quantitative morphometric or densitomet-

ric assessment of the quality of allograft material was not conducted, which should be considered as an additional limitation and a perspective direction for further studies.

## Conclusion

The given results confirm the clinical efficacy of a two-stage surgical approach using allogeneic bone material obtained from femoral heads resected during primary replacement. The use of a

titanium cage filled with this material in combination with minimally invasive transpedicular fixation ensures restoration of spinal stability, promotes reliable osseointegration and the formation of strong bone fusion, which allows achieving persistent regression of pain syndrome and neurological disorders, as well as executing early verticalization and rehabilitation of the patient.

The high degree of transplant integration and radiologically determined bone fusion, positive clinical dynamics, as well

as the absence of complications associated with obtaining autogenous bone material, allow considering the described technique as a reliable and safe alternative to autotransplantation in patients with infectious lesions of the spine. Conducting further prospective studies with sample expansion and direct comparison of various types of transplants appears necessary to clarify the indications and expand the evidence base for the application of allograft material in vertebral surgery.

## References

- Duarte RM, Vaccaro AR. Spinal infections: state of the art and management algorithm. *Eur Spine J*. 2013;22:2787–2799. DOI: 10.1007/s00586-013-2850-1
- Pola E, Logroscino CA, Gentiempo M, Colangelo D, Mazzotta V, Di Meco E, Fantoni M. Medical and surgical treatment of pyogenic spondylodiscitis. *Eur Rev Med Pharmacol Sci*. 2012;16 Suppl 2:35–49.
- Bazarov AY, Sergeev KS, Tsvetkova AK. Long-term outcomes and effectiveness of treatment methods for vertebral osteomyelitis with different types of lesions according to the E. Pola Classification. *Traumatology and Orthopedics of Russia*. 2023;29(2):7–17. DOI: 10.17816/2311-2905-7445 EDN: LCSXMA
- Tuchman A, Pham M, Hsieh PC. The indications and timing for operative management of spinal epidural abscess: literature review and treatment algorithm. *Neurosurg Focus*. 2014;37:E8. DOI: 10.3171/2014.6.FOCUS14261
- Butler JS, Shelly MJ, Timlin M, Powderly WG, O'Byrne JM. Nontuberculous pyogenic spinal infection in adults: a 12-year experience from a tertiary referral center. *Spine*. 2006;31:2695–2700. DOI: 10.1097/01.brs.0000244662.78725.37
- Skaf GS, Domloj NT, Fehlings MG, Bouclaous CH, Sabbagh AS, Kanafani ZA, Kanj SS. Pyogenic spondylodiscitis: an overview. *J Infect Public Health*. 2010;3:5–16. DOI: 10.1016/j.jiph.2010.01.001
- Kowalski TJ, Berbari EF, Huddleston PM, Steckelberg JM, Osmon DR. Do follow-up imaging examinations provide useful prognostic information in patients with spine infection? *Clin Infect Dis*. 2006;43:172–179. DOI: 10.1086/505118
- Homagk L, Marmelstein D, Homagk N, Hofmann GO. SponDT (Spondylodiscitis Diagnosis and Treatment): spondylodiscitis scoring system. *J Orthop Surg Res*. 2019;14:100. DOI: 10.1186/s13018-019-1134-9
- Yoon SH, Chung SK, Kim KJ, Kim HJ, Jin YJ, Kim HB. Pyogenic vertebral osteomyelitis: identification of microorganism and laboratory markers used to predict clinical outcome. *Eur Spine J*. 2010;19:575–582. DOI: 10.1007/s00586-009-1216-1
- Aagaard T, Roed C, Dahl B, Obel N. Long-term prognosis and causes of death after spondylodiscitis: a Danish nationwide cohort study. *Infect Dis (Lond)*. 2016;48(3):201–208. DOI: 10.3109/23744235.2015.1103897
- An HS, Seldomridge JA. Spinal infections: diagnostic tests and imaging studies. *Clin Orthop Relat Res*. 2006;444:27–33. DOI: 10.1097/01.blo.0000203452.36522.97
- Mushkin AY, Vishnevsky AA, Peretsmanas EO, Bazarov AY, Basankin IV. Infectious lesions of the spine: draft national clinical guidelines. *Russian Journal of Spine Surgery (Khirurgiya Pozvonochnika)*. 2019;16(4):63–76. DOI: 10.14531/ss2019.4.63-76 EDN: KUOPMM
- Byal'tsev VA, Stepanov IA, Borisov VE, Kalinin AA, Pleshko IV, Belykh EG, Aliev MA. Surgical site infections in spinal neurosurgery. *Kazan Medical Journal*. 2017;98(5):796–803. DOI: 10.17750/KMJ2017-796 EDN: ZGSBGN
- Clinical guidelines "Inflammatory lesions of the spine". The Association of Orthopedic Traumatologists of Russia, the Russian Association of Vertebral Surgery Surgeons, the National Association of Phthisiologists, etc., 2024. Available in the register of clinical recommendations of the Ministry of Health of the Russian Federation: <https://cr.minzdrav.gov.ru>.
- Lener S, Hartmann S, Barbagallo GMV, Certo F, Thome C, Tschugg A. Management of spinal infection: a review of the literature. *Acta Neurochir (Wien)*. 2018;160:487–496. DOI: 10.1007/s00701-018-3467-2
- Sobottke R, Seifert H, F tkenheuer G, Schmidt M, Gossmann A, Eysel P. Current diagnosis and treatment of spondylodiscitis. *Dtsch Arztebl Int*. 2008;105:181–187. DOI: 10.3238/arztebl.2008.0181
- Govender S. Spinal infections. *J Bone Joint Surg Br*. 2005;87:1454–1458. DOI: 10.1302/0301-620X.87B11.16294
- Arrington ED, Smith WJ, Chambers HG, Bucknell AL, Davino NA. Complications of iliac crest bone graft harvesting. *Clin Orthop Relat Res*. 1996;329:300–309. DOI: 10.1097/00003086-199608000-00037
- Kim SS, Kang DH, Yoon JW, Park H, Lee CH, Hwang SH. Surgical treatment of pyogenic spondylitis with the use of freeze-dried structural allograft. *Korean J Spine*. 2014;11(3):136–140. DOI: 10.14245/kjs.2014.11.3.136
- Chung TC, Yang SC, Chen HS, Kao YH, Tu YK, Chen WJ. Single-stage anterior debridement and fibular allograft implantation followed by posterior pedicle screw instrumentation for complicated infectious spondylitis: report of 20 cases. *Medicine (Baltimore)*. 2014;93(27):e190. DOI: 10.1097/MD.0000000000000190
- Martínez-Gutiérrez O, Peña-Martínez V, Camacho-Ortiz A, Vilchez-Cavazos F, Simental-Mendía M, Tamez-Mata Y, Acosta-Olivo C. Spondylodiscitis treated with freeze-dried bone allograft alone or combined with autograft: A randomized and blinded trial. *J Orthop Surg (Hong Kong)*. 2021;29(2):23094990211019101. DOI: 10.1177/23094990211019101
- Placide R, Reznicek J. Evaluation and management of pyogenic spondylodiscitis: a review. *J Clin Med*. 2025;14(10):3477. DOI: 10.3390/jcm14103477
- Hijazi MM, Siepmann T, Disch AC, Platz U, Juratli TA, Ey poglu IY, Podlesek D. Diagnostic sensitivity of blood culture, intraoperative specimen, and computed tomography-guided biopsy in patients with spondylodiscitis and isolated spinal epidural empyema requiring surgical treatment. *J Clin Med*. 2023;12:3693. DOI: 10.3390/jcm12113693

24. **Bellendir EN.** *Features of restorative processes in plastic replacement of bone cavities after removal of tuberculous foci in an experiment:* Abstract of a doctor of medical sciences dissertation. Leningrad, 1968. URL: [https://rusneb.ru/catalog/000199\\_000009\\_005964247/](https://rusneb.ru/catalog/000199_000009_005964247/)
25. **Bellendir EN, Salmagambetov IU.** Theoretical substantiation of using the component plastic surgery in osteoarticular surgery. *Grekov's Bulletin of Surgery.* 1990;144(10):87–91.
26. **Boyarkina SK.** Reparative bone regeneration, vascularization, and bone grafting in tuberculosis, staphylococcal, and mixed infections. *Problemy Tuberkuleza.* 1981;(9):54.
27. **Guseva VN, Garbuz AE.** Results of decompression operations in patients with tuberculous spondylitis. *Problemy Tuberkuleza.* 2001;(9):47–51.
28. **Tsivyan YaL, Ramikh EA, Mikhaylovskiy MV.** *Reparative Regeneration of the Fractured Vertebral Body.* Novosibirsk, 1985. URL: [https://rusneb.ru/catalog/000199\\_000009\\_001262274/](https://rusneb.ru/catalog/000199_000009_001262274/)
29. **Letina VK, Ardashov IP.** Use of bone allotransplantation in reconstructive operations on the spine. *Orthopedics, Traumatology and Prosthetics.* 1986;(4):12–18.
30. **McHenry MC, Easley KA, Locker GA.** Vertebral osteomyelitis: long-term outcome for 253 patients from 7 Cleveland-area hospitals. *Clin Infect Dis.* 2002;34:1342–1350. DOI: 10.1086/340102
31. **Hadjipavlou AG, Mader JT, Necessary JT, Muffoletto AJ.** Hematogenous pyogenic spinal infections and their surgical management. *Spine.* 2000;25:1668–1679. DOI: 10.1097/00007632-200007010-00010
32. **von Stechow D, Rauschmann MA.** Effectiveness of combination use of antibiotic-loaded PerOssal with spinal surgery in patients with spondylodiscitis. *Eur Surg Res.* 2009;43:298–305. DOI: 10.1159/000233525
33. **Tang X, Li J, Wang C, Liu F, Guo J, Tan J, Song Q, Cao H, Zhang Y.** Antibiotic-loaded calcium sulfate beads in spinal surgery for patients with spondylodiscitis: a clinical retrospective study. *BMC Musculoskelet Disord.* 2022;23:270. DOI: 10.1186/s12891-022-05230-y
34. **Funayama T, Noguchi H, Shibao Y, Sato K, Kumagai H, Miura K, Takahashi H, Tatsumura M, Koda M, Yamazaki M.** Unidirectional porous beta-tricalcium phosphate as a potential bone regeneration material for infectious bony cavity without debridement in pyogenic spondylitis. *J Artif Organs.* 2023;26:89–94. DOI: 10.1007/s10047-022-01335-2
35. **Deml MC, Cattaneo EN, Bigdon SF, Sebald HJ, Hoppe S, Heini P, Benneker LM, Albers CE.** PMMA-Cement-PLIF is safe and effective as a single-stage posterior procedure in treating pyogenic erosive lumbar spondylodiscitis—a single-center retrospective study of 73 cases. *Bioengineering (Basel).* 2022;9:73. DOI: 10.3390/bioengineering9020073

Received 05.10.2025

Review completed 13.01.2026

Passed for printing 26.01.2026

## Additional information

**Author contributions.** V.K. Shapovalov — study design development, clinical data collection, participation in surgical treatment, statistical processing, preparation of the initial draft of the manuscript, literary processing and final editing of the text, duties of the corresponding author; I.V. Basankin — formulation of the study concept, scientific supervision, methodology development, critical revision of the text with the introduction of fundamentally important comments, expert validation of surgical tactics, final approval of the manuscript; A.A. Afaunov — methodological support, expert evaluation of surgical approaches, critical scientific editing of the text, advising on the structure of the study; I.V. Gilevich — laboratory support, analysis of microbiological and biochemical data, advising on the preparation and properties of bone allograft; A.A. Gyulzatyan — participation in surgical interventions, collection of observation data, clinical examination of patients, assistance in visualizing data; N.V. Tushkanova — data collection, analytical literature search, preparation of illustrative material and tables, participation in text editing. All authors approved the manuscript (the version for publication), and also agreed to bear responsibility for all aspects of the work, guaranteeing proper consideration and resolution of issues related to the accuracy and integrity of any part of it.

**Ethical review.** The conduct of the study was approved by the local ethics committee of the Research Institute – S.V. Ochapovsky Regional Clinical Hospital No. 1 (protocol No. 154 dated February 16, 2023).

**Consent for publication.** All patients gave voluntary informed consent to use clinical data and biological material for scientific purposes.

**Funding sources.** None.

**Disclosure of interests.** The authors declare no conflict of interest.

## Authors' Info

✉ Vladimir Konstantinovich Shapovalov, MD, Cand. Sci. (Medicine); 167 Pervogo Maya str., Krasnodar, Russia, 350086; eLibrary SPIN: 2639-0804; ORCID: 0000-0003-4556-251X; shapovalovspine@gmail.com

Igor Vadimovich Basankin, MD, Dr. Sci. (Medicine); eLibrary SPIN: 3541-8946; ORCID: 0000-0003-3549-0794; basankin@rambler.ru

Asker Alievich Afaunov, MD, Dr. Sci. (Medicine), Professor; eLibrary SPIN: 8039-9920; ORCID: 0000-0001-7976-860X; afaunovkr@mail.ru

Irina Valeryevna Gilevich, MD, Cand. Sci. (Medicine); eLibrary SPIN: 3911-1488; ORCID: 0000-0002-9766-1811; giliv@list.ru

Abram Akopovich Gyulzatyan, MD, Cand. Sci. (Medicine); eLibrary SPIN: 6853-4861; ORCID: 0000-0003-1260-4007; abramgulz@gmail.com

Nadezhda Vladimirovna Tushkanova; ORCID: 0009-0009-8810-5221; tushk98@gmail.com



