DIGEST OF SPINE SURGERY JOURNAL | 2/2014 (C. 47–54)

© S.T. VETRILE ET AL., 2009

SURGICAL TREATMENT OF EXTENDED KYPHOTIC DEFORMITIES OF THE THORACIC AND LUMBAR SPINE*

S.T. Vetrile, A.A. Kuleshov, M.S. Vetrile, O.B. Chelpachenko
N.N. Priorov Central Institute of Traumatology and Orthopedics, Moscow, Russia

Objective. To assess the efficacy of surgical treatment of kyphosis of various etiology and to develop a differential etiology-based approach to the choice of surgical correction technique.
Material and Methods. Seventy four patients with extended kyphotic deformities were operated on, including 13 patients with posttraumatic kyphosis; 13 — with congenital kyphosis and kyphoscoliosis with a prevalence of kyphotic component; 7 — with Scheuermann's kyphosis; 12 — with dysplastic kyphoscoliosis; 11 — with neurogenic kyphosis and kyphoscoliosis; and 18 — with iatrogenic kyphotic deformities. Various types of corrective vertebrectomy were performed in 68 patients.
Results. Average Cobb angle in patients with extended kyphosis decreased from 65.78° ± 30.70° to 40.00° ± 19.93°. The application of corrective vertebrectomy in 61 patients allowed for a rise in efficacy of intraoperative deformity correction by 32.0 ± 13.5 %. Differential approach to the choice of treatment technique resulted in good outcome in 66 patients (83.8 %) and in satisfactory, in 10 patients (13.5 %).
Conclusion. Differential approach to surgical treatment of extended kyphotic deformities in the thoracic and lumbar spine increases the efficacy of surgical correction, decreases the risk of neurologic disorder development and progression, and restores the spine support function.

Key Words: kyphosis, surgical treatment, vertebrectomy.

The kyphotic bowing of the thoracic spine has a physiological nature; however, no consensus has been achieved on the boundaries between normal and pathological kyphosis [9, 18]. Surgical treatment of kyphotic deformities of the thoracic and lumbar spine is one of the most intricate problems of modern orthopedics [8], whose urgency is associated with the high rate of non-satisfactory treatment outcomes.

The objective of this study was to assess the efficiency of surgical treatment of kyphosis of different etiology and to develop the differential approach to the choice of surgical correction of kyphotic deformities.

Material and Methods

74 patients with extended kyphotic deformities were operated on at the Spine Surgery Department, Central Institute of Traumatology and Orthopedics. The patients were distributed into six nosological groups: 13 patients with posttraumatic kyphosis; 13 – with congenital kyphotic and kyphoscoliotic deformities with the prevalence of kyphotic component; 7 – with Scheuermann's kyphosis; 12 – with dysplastic kyphoscoliosis; 11 – with neurogenic kyphosis and kyphoscoliosis; and 18 – with iatrogenic kyphotic deformities (postlaminectomic kyphosis). Groupwise general characteristics of patients are summarized in Table 1.

To choose a strategy of surgical treatment, the clinical and radiographic data were analyzed by the following criteria: extension of deformity (standard spondylography), mobility/rigidity (functional spondylograms, myelograms, and traction test), presence of spinal stenosis and (or) intracanal masses (CT, MRI and CT combined with myelography), degree of sagittal and frontal imbalances (anthropometry, standing radiography), nature of neurologic disorders and previous surgical interventions. In patients with congenital and neurogenic kyphotic deformities, as well as in patients with severe rigid kyphosis of other etiology with neurologic deficits, spinal angiography was performed to reveal the details of spinal circulation in the area of the tentative surgical intervention.

Angle of kyphotic deformity and value of lumbar lordosis were assessed using the Cobb technique. In order to unify calculations, results of deformity correction were compared with allowance for sagittal index (SI) at the thoracic (+5°), thoracolumbar (0°), and lumbar (-10°) levels. SI allows one to calculate the necessary corrections, in particular, the flexion degree of an instrumentation rod. The difference between the kyphosis angle calculated according to the radiogram and SI yields the actual kyphotic deformity value [14]. To enhance the objectivity of assessment of spinal stenosis degree at the apex of kyphotic deformity, relative area of spinal stenosis was assessed by K. Yucesoy and N.R. Crawford [21] based on the radiography (myelography), CT, or MRI data.

**Vetrile ST, Kuleshov AA, Vetrile MS, Chelpachenko OB. [Surgical Treatment of Extended Kyphotic Deformities of the Thoracic and Lumbar Spine]. Hirurgia pozvonocnika. 2009;(3):20–29. In Russian. DOI: https://doi.org/10.14531/ss2009.3.20-29*

A statistical analysis was performed in order to study properties of kyphotic deformity and its effects on sagittal spine profile, as well as to reveal the correlation between various parameters.

The grade system (score 6 to 28) was developed for objective evaluation of treatment outcomes. It is a combination of the following scales and questionnaires (Table 2):

- Denis assessment of pain syndrome and performance (score 1–5) [12];
- Frankel classification of neurologic disorders (score 1–5) [13];
- Assessment of pelvic organ dysfunctions by Japan Orthopedic Association (JOA) score (score 1–3) [11];
- Assessment of appearance (score 1–5) by SRS (Scoliosis Research Society);
- Assessment of radiographic data (score 1–5).

Table 1

General characteristics of patients with extended thoracic and lumbar kyphotic deformities (M ± m)

Kyphosis nosology	Number of patients, n	Average number of spinal motion segments, n	Average Cobb kyphosis angle, deg.	Area of spinal canal kyphosis, %	Value of spinal canal stenosis, %	Cobb angle of scoliosis component, deg.
Posttraumatic	13	2.23 ± 0.59	31.70 ± 12.00	35.67 ± 6.40	36.07 ± 5.80	–
Congenital	13	3.23 ± 2.04	71.42 ± 12.00	55.22 ± 23.35	42.31 ± 12.08	60.00 ± 36.00
Osteochodropathy	7	6.43 ± 1.20	85.29 ± 10.39	–	–	40.20 ± 20.05
Dysplastic	12	5.61 ± 1.33	84.22 ± 25.00	–	–	53.13 ± 37.38
Neurogenic	11	5.16 ± 0.89	83.81 ± 15.55	49.18 ± 21.03	31.20 ± 10.32	96.54 ± 18.86
Postlaminectomic	18	2.89 ± 1.02	79.25 ± 29.40	51.65 ± 19.72	51.27 ± 20.47	96.55 ± 25.96

Table 2

Standardized evaluation of surgical treatment outcomes, score

Score	Pain according to Denis Pain Scale	Performance according to Denis	Neurology according to Frankel	Pelvic organ function according to JOA	Patient's appearance (presence of a cosmetic defect) by SRS*	Radiographic data (fusion consistency, correction of kyphotic deformity, stenosis of spinal canal)
1	P5	W5	A	Failure of regulation of the pelvic organ functions	1–2	Progressive kyphotic deformity involving adjacent spinal motion segments; pseudoarthrosis; stenosis of spinal canal exceeding the threshold values for this localization
2	P4	W4	B	Partial pelvic organ dysfunction	3–4	Pseudoarthrosis, kyphosis more than 30° (but less than the baseline one); degenerative changes in adjacent segments; stenosis of spinal canal not exceeding the threshold values without apparent signs of deformity progression
3	P3	W3	C	Standard regulation of pelvic organ functions	5–6	Osteofibrous block, residual nonprogressive kyphosis within 30°; no spinal canal stenosis; no spinal canal stenosis; no signs of kyphosis progression
4	P2	W2	D	–	7–8	Consistent fusion, residual nonprogressive kyphosis lower than 20° (considering the sagittal index); no spinal canal stenosis; no signs of kyphosis progression
5	P1	W1	E	–	9–10	Consistent fusion; complete correction of deformity with formation of physiological sagittal spinal profile; no spinal canal stenosis; no signs of kyphosis progression

Maximum possible total score – 28: score 23–28– good outcome; score 12–22– satisfactory; score less than 11– unsatisfactory;

* self-assessment of patient's appearance (score 1 to 10): 1 – very low self-assessment, 10 – very high self-assessment.

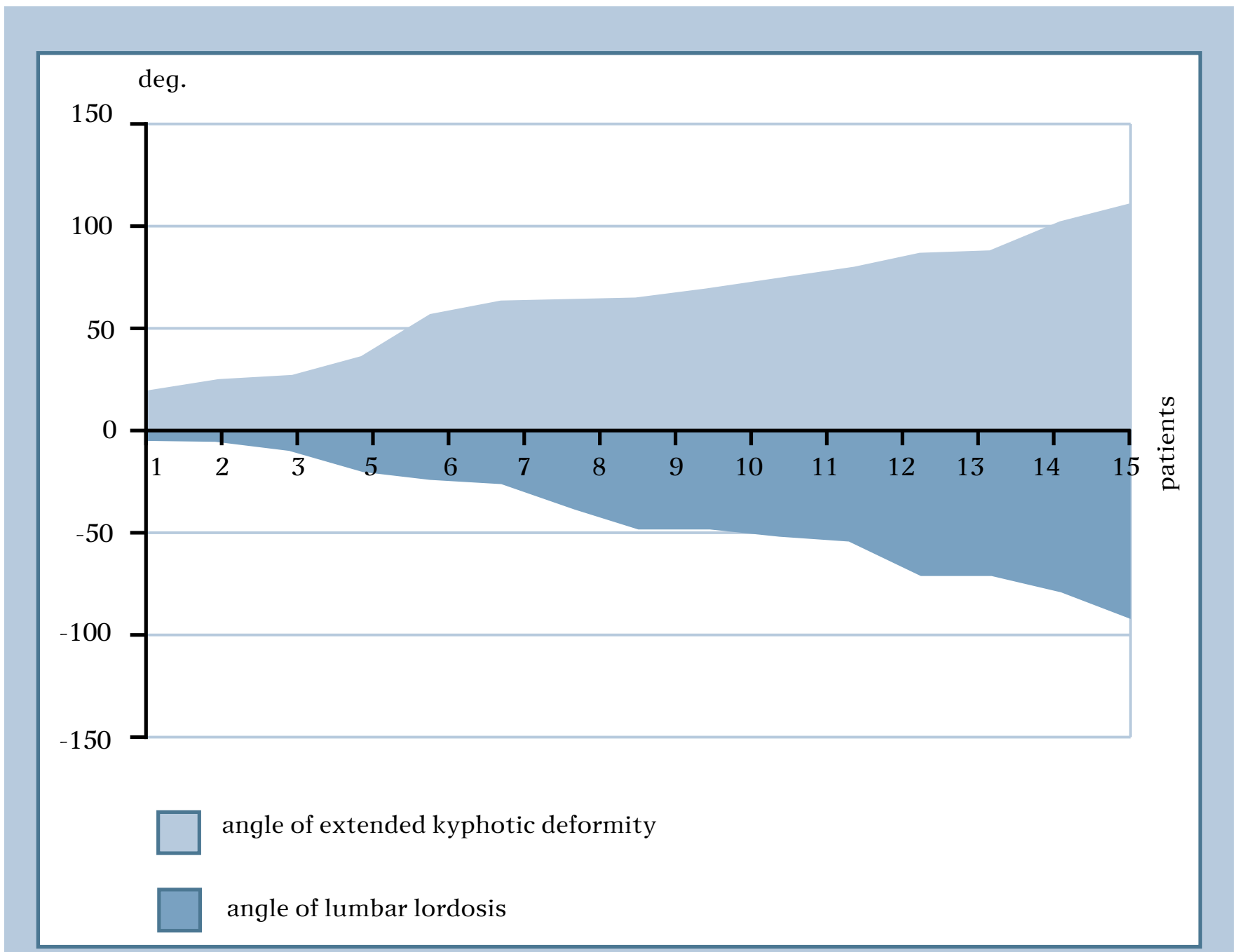

Fig. 1
Correlation between the angles of extended kyphotic deformity and the lumbar lordosis

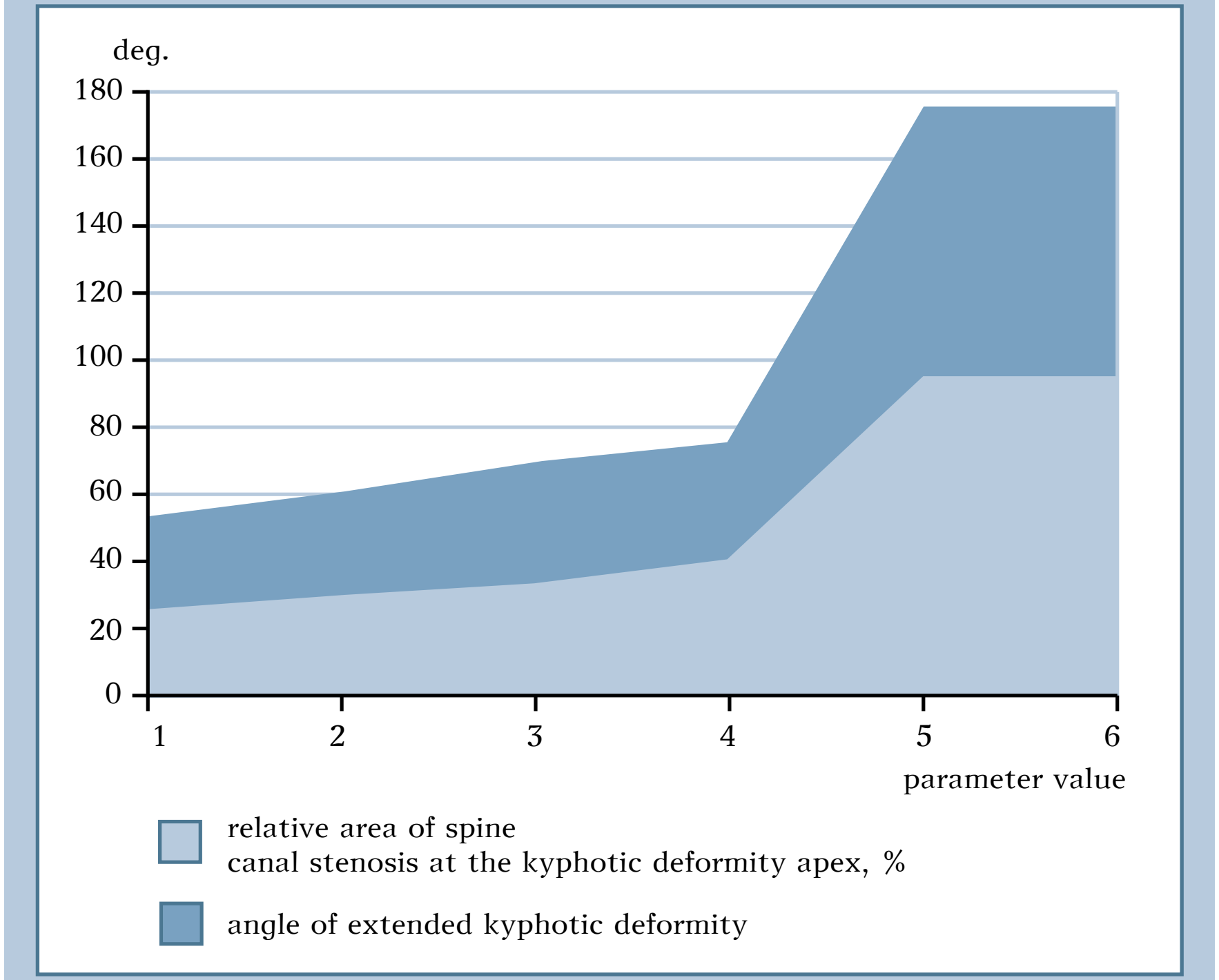

Fig. 2
Correlation between the relative area of spine canal stenosis and the angle of extended kyphotic deformity

Various types of corrective vertebrectomy were performed to enhance effeciency of surgical correction of severe kyphotic deformities, including Boichev vertebrectomy in 2 patients; Tsiv'yan vertebrectomy in 2 patients [4, 7]; posterior wedge resection (removal of a vertebral body) at the apex of kyphotic deformity in 22 patients [17, 19]; vertebrectomy of anterior and middle spinal columns through an anterior approach in 2 patients; anterior release followed by dorsal correction and fixation with polysegmental metal construct in 29 patients [20]; Smith-Petersen posterior corrective osteotomy in 4 patients [14, 15]; N. Kawahara procedure in 4 patients [16]; and posterior wedge vertebrectomy with resection at the level of the basement of apical vertebral in 2 patients [10].

Results

The average Cobb angle in patients with extended kyphosis decreased from 65.78° ± 30.70° to 40.00° ± 19.93°. The use of various types of corrective vertebrectomy in 61 patients allowed for a rise of effectiveness of intraoperative deformity correction by 32.0 ± 13.5 %.

In response to surgical treatment, physiological sagittal spine profile was formed in 51 (68.9 %) patients, while the near-physiological one was formed in 21 patients (28.4 %). Two (2.7 %) patients with congenital kyphotic deformities kept stable sagittal imbalance.

Reliable negative correlation (according to the Spearman's rank correlation coefficient) between the kyphotic deformity angle and lumbar lordosis ($r = 0.62$; $P < 0.05$; Fig. 1) was observed in studies of kyphotic deformity characteristics.

Reliable correlation between the relative area of spinal canal stenosis and the angle of extended kyphotic deformity ($r = 0.83$; $P < 0.05$) consistent with high interrelation of parameters was found (Fig. 2).

An analysis of the neurological status revealed original neurological symptoms in 28 (37.8 %) patients, their postoperational development was found in 1 (1.4 %) patient. Eighteen (64.3 %) patients had no positive dynamics in

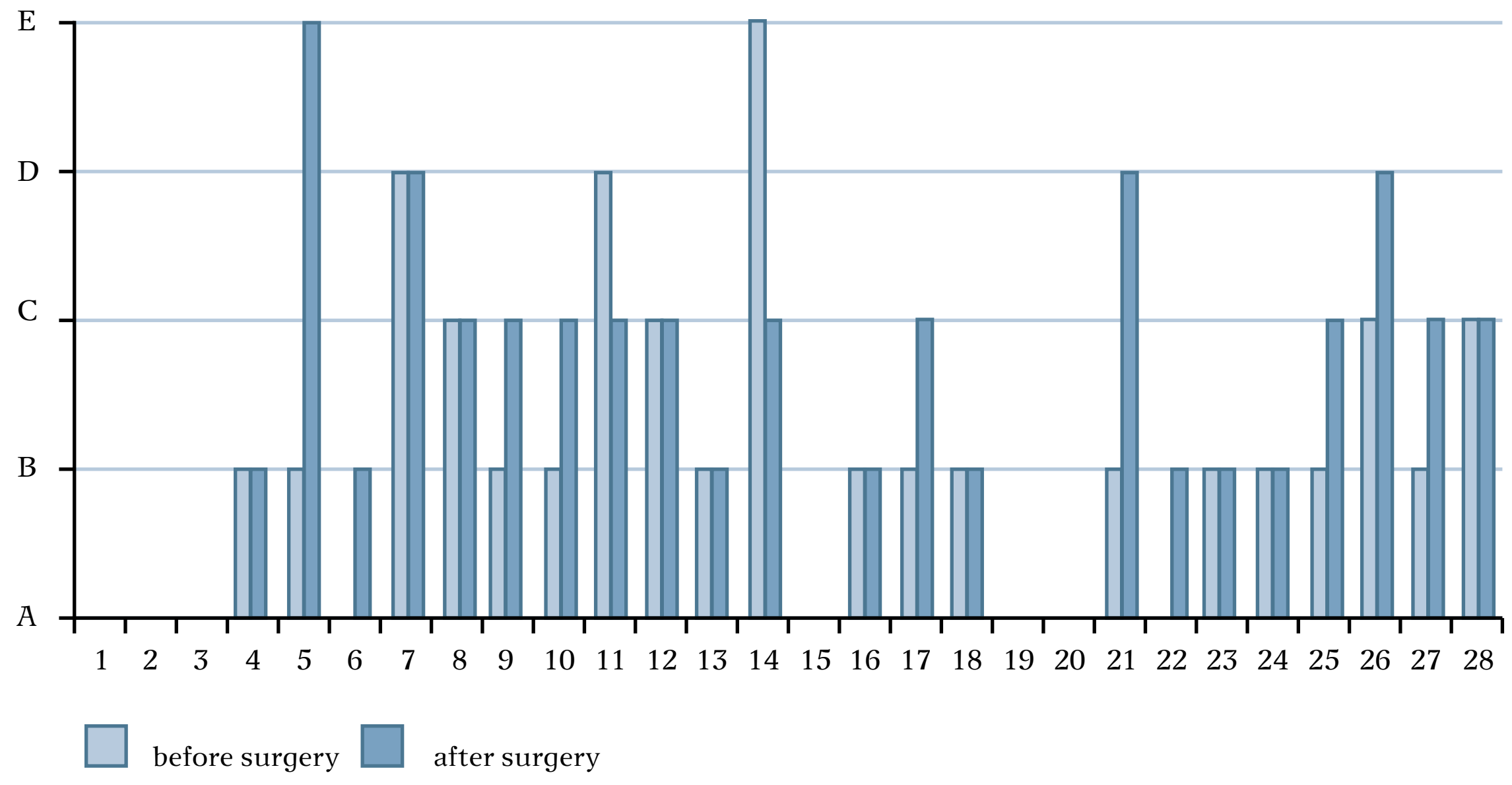

Fig. 3
Neurological status of patients with original neurological symptoms

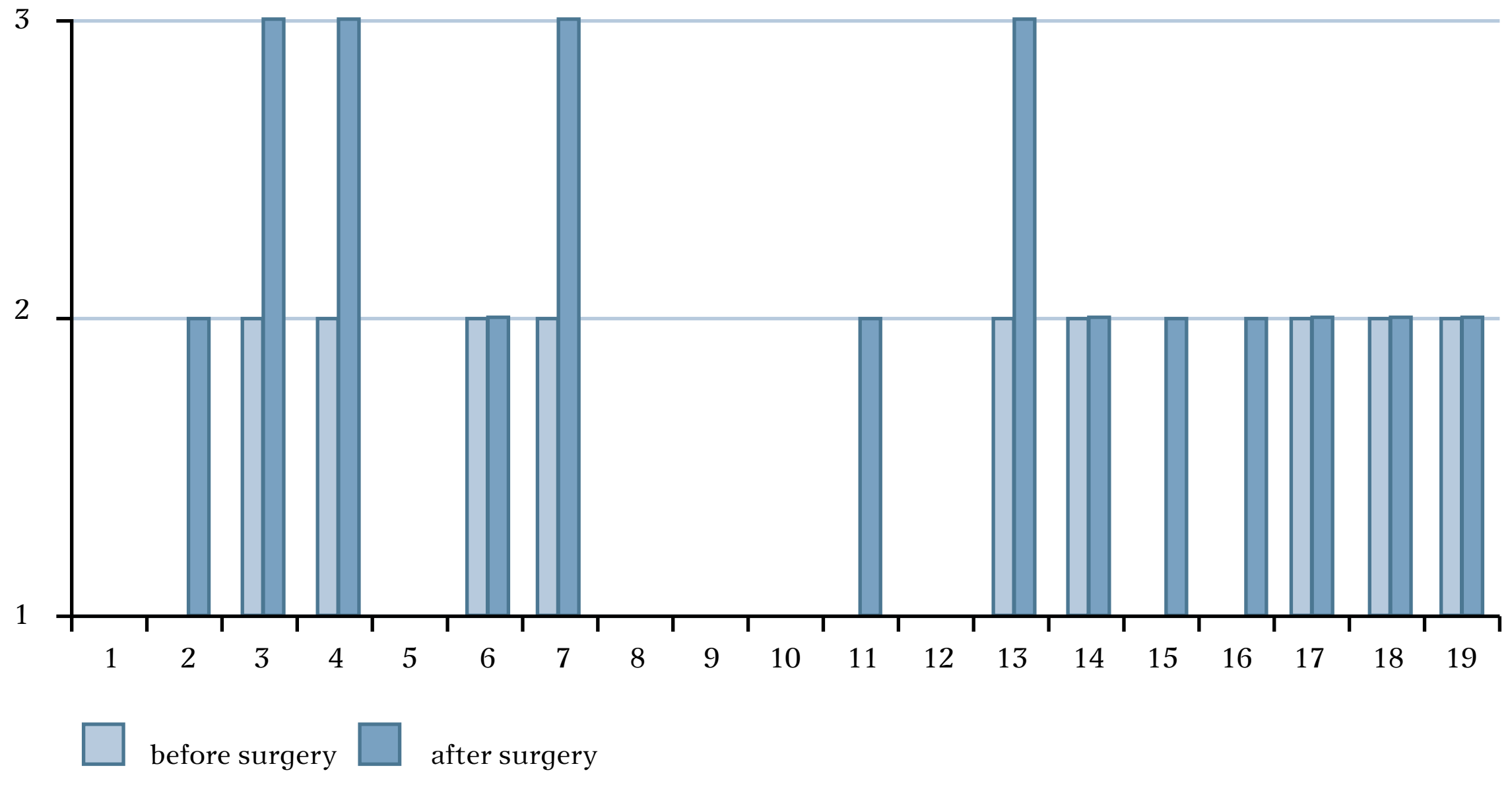

Fig. 4
Pelvic organ function in patients with original neurological signs

their neurological status, and 10 (35.7 %) had regressed symptoms of myelopathy after surgical treatment (Fig. 3).

Eighteen patients had original disturbance of pelvic organ function (POF) of different intensity; POF regulation was improved after surgical treatment in 6 of them. In 4 patients with positive dynamics of POF regulation after surgical treatment, complete recovery of the functions was reliable, 2 patients had light intensive disturbance (Fig. 4). No isolated POF disturbance in the absence of motion and sensory disorders was detected.

An analysis of treatment outcomes in patients with extended kyphotic deformities showed an increase in the total score from 16.22 ± 3.43 to 23.17 ± 3.77 according to all the aforementioned criteria.

Therefore, 62 (83.8 %) patients with extended kyphotic deformities of different etiology have good treatment outcome, 10 (13.5 %) — satisfactory, and 2 (2.7 %) — unsatisfactory.

Denis pain scale scores were analyzed separately. The average score of this parameter increased from 2.76 ± 1.22 to 4.51 ± 0.5, attesting to the dependence between the severity of kyphotic deformity and pain syndrome intensity.

Reliable correlation ($r = 0.68$; $P < 0.01$) between the Denis pain syndrome level and the angle of residual kyphotic deformity was found when comparing these parameters. The mean correlation was found between Frankel intensity of neurological deficit and the angle of residual kyphotic deformity ($r = 0.42$; $P < 0.01$).

An analysis of the performance and physical activity scale showed an increase in the average score from 2.36 ± 1.03 to 4.10 ± 1.36. The appearance self-assessment score increased from 2.77 ± 0.10 to 4.53 ± 0.67.

The average score of radiologic data was 1.80 ± 0.58 before surgical treatment and 4.52 ± 0.62 after treatment, indicating the efficiency of the surgical correction strategy chosen.

Thus, efficiency of the comprehensive approach to surgical treatment of extended kyphotic deformities has been proved by the increase in all post-treatment standardized indices versus their baseline level.

Discussion

Regardless of their etiology, kyphotic deformities are always progressive in their natural course and may cause neurological complications. Nonsurgical treatment of a kyphotic deformity neither improves the deformity nor prevents its progression. Sagittal imbalance following kyphosis changes the load on the adjacent spine portions and on joints of the lower limbs. Deformity correction; restoration of the spine support function with maximal possible improvement of the kyphotic deformity and standardization of the spine sagittal profile; repair of vertebromedullary conflict and pain syndrome; arrangement of conditions for restoration of lost spine functions, formation of a solid spinal fusion; and early patient's activation [7, 18] are the objectives of surgical treatment. Patients both with severe neurological symptoms and those without these symptoms but with spinal canal stenosis exceeding the threshold values for localization of stenosis caused by kyphotic deformity were exposed to revision and decompression of spinal canal [1]. In some cases decompression of spinal canal accompanied corrective vertebrectomy.

Allowance should be made for the factors affecting the progression of kyphotic deformity when performing a surgery. The factors preventing the progression of kyphotic deformity include stability of posterior spinal column, strengthening of the back extensors, and presence of physiological lumbar lordosis [5]. Relative shortening of the anterior vertebral column caused by destruction of the vertebral bodies, their pathologies or congenital malformations, instability of the anterior vertebral column, fibrosis of the anterior longitudinal ligament or blocking of the anterior vertebral column, and presence of physiological thoracic kyphosis are the main factors of kyphotic deformity progression [6]. Identically to most researchers [10, 15—17, 20], the authors adhere to the strategy of surgical treatment by dorsal approach provided that the support function and stability of the anterior and middle vertebral columns were retained. When the anterior vertebral column is relatively shortened, the defect of anterior support structures following the instrumental correction of the deformity can be replaced with autografts or Pyramesh interbody cages. Anterior spine mobilization followed by conditioning of fusion formation is required for patients with severe rigid deformities [2, 3]. It is well known that a spinal kyphotic deformity can be improved by two ways: axial stretching and extension. A. White and M. Panjabi (cited by: M.V. Mikaylovsky and N.G. Fomichev, 2002) have developed a mathematical model to study the relative efficiency of axial and transverse loading in correction of spinal deformities. The studies have shown that when Cobb deformation is ⩾53° in patients with extended kyphosis, an axial traction is more efficient compared to the transverse effort (extension). In patients with short extended kyphosis (2 or 3 segments), the axial corrective manipulation is more efficient than the horizontal one. However, both forces should be applied to make surgical correction of severe extended kyphotic deformities more effective. We usually perform an axial correction in a halo device, which is used as a means of preoperative preparation or as a correction and fixation technique during the interoperative periods. Application of halo devices (we use the halo-pelvic traction system) is based on elastic properties of soft tissues [3]. Advanced polysegmental instrumentation allows one to perform targeted intraoperational correction of a kyphotic deformity by both distraction and extension, and provides stable spinal fixation when correction attains the optimal level [5]. We applied corrective vertebrectomy to enhance efficiency of kyphosis correction. It is necessary to properly choose the axis around which deformity is corrected. Osteotomy is aimed at shifting the axial load vector dorsally to restore sagittal balance [10]. Vertebrectomy of the anterior spinal support complex is performed to ensure mobilization. It allows one to establish conditions for consistent fusion and, in some cases, to stretch the anterior and posterior vertebral columns [16, 17, 19, 20]. The formation of the so-called “360° fusion” is the gold standard in surgery of spinal deformities [1, 3, 7, 10, 14, and 16]. Osteotomy of the posterior vertebral column with polysegmental instrumentation for contraction promotes adequate spine mobilization and shortening of the relatively elongated posterior vertebral column [14, 15]. We used this type of osteotomy to manage Scheuermann’s juvenile hyperkyphosis and dysplastic kyphoscoliosis.

Case 1. Two-stage surgery under a single anesthesia was performed in 13-year-old female patient Z. with Scheuermann’s thoracic kyphosis. The first stage comprised transthoracic multilevel discectomy at the T5—T11 deformity apex, and interbody fusion with an autobone; the second stage comprised dorsal corrective osteotomy at the T5—T11 deformity apex (6 levels); correction and fixation of the thoracic spine under conditions of intraoperational halo-pelvic traction, and posterior instrumental fusion (Fig. 5).

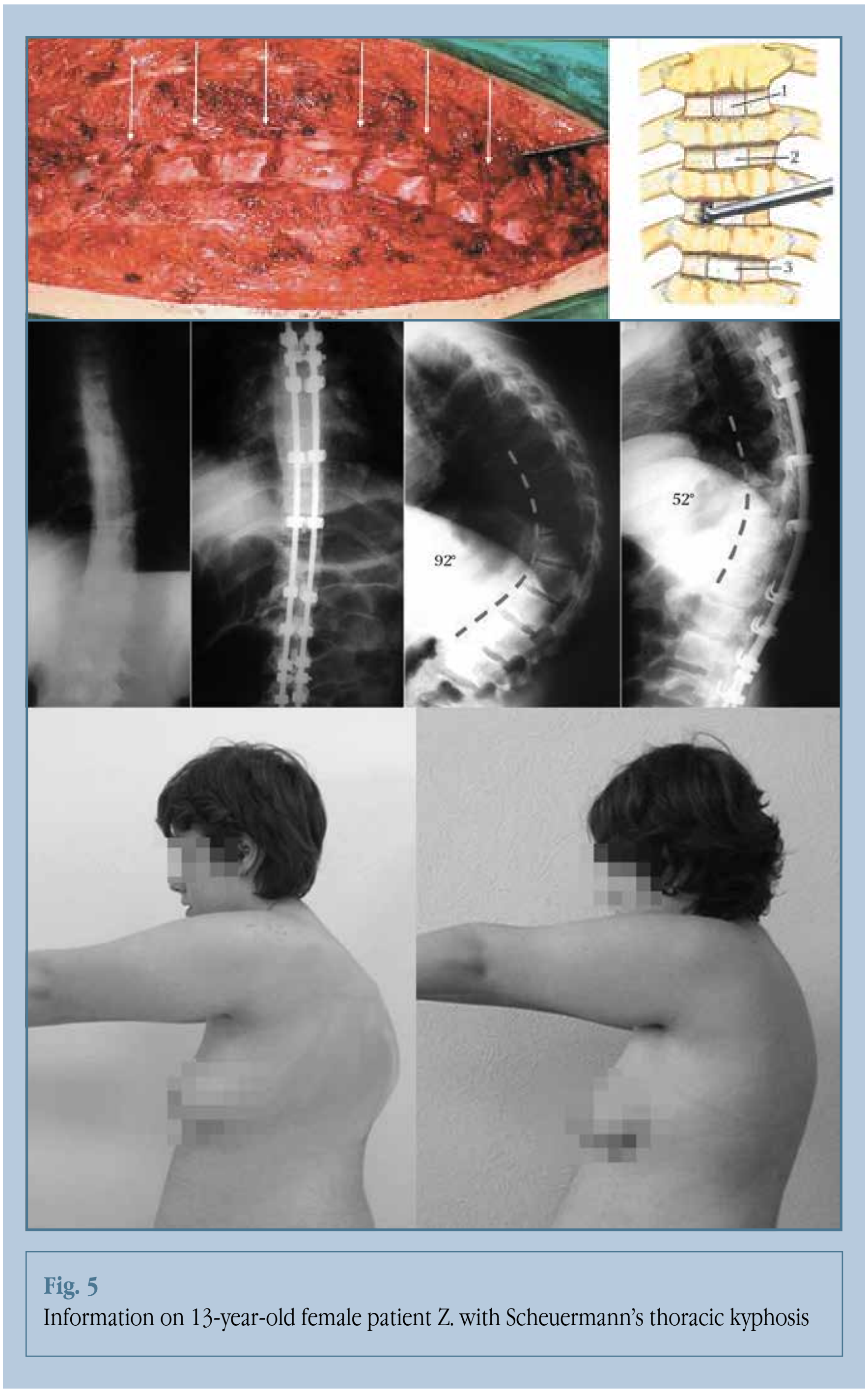

Fig. 5
Information on 13-year-old female patient Z. with Scheuermann’s thoracic kyphosis

We use three-column vertebrectomy [16, 20] to attain the maximum correction degree in patients with severe kyphotic deformities and severe sagittal imbalance.

Case 2. Male 17-year-old patient S. with postlaminectomic kyphosis, in condition after neurinoma resection, with inadequate metal fixation. Weakness of the right lower limb since 2002 was reported. The patient was operated on by neurosurgeons according to his residence place: laminectomy at the T12 level, neurinoma resection, and transpedicular fixation. In November 2003, after a fall from a motorcycle, pains occurred in the patient’s lumbar spine irradiating into his lower limbs. Aggravation of the kyphotic deformity was revealed. A two-stage surgical treatment was performed. The first stage comprised the application of a halo device for preliminary correction of the deformity. A month later, during the second stage, the metal construct was removes; the intracanal tumor was dissected and the following procedures were performed: corrective vertebrectomy according to N. Kawahara et al. [16], spine correction and fixation with CD instrumentation, interbody fusion with a Mesh cage, and posterior fusion. Development of claudication with neuropathic pain was noted in the postoperative period; POF was not impaired. Complex rehabilitation treatment was performed; the positive dynamics of treatment was noted (pain was arrested; muscle strength of the lower limbs was restored up to baseline level). The patient was activated and was able to walk without any supplementary supports (Fig. 6).

However, this type of surgical interventions is traumatic and associated with a high risk, thus requiring comprehen-

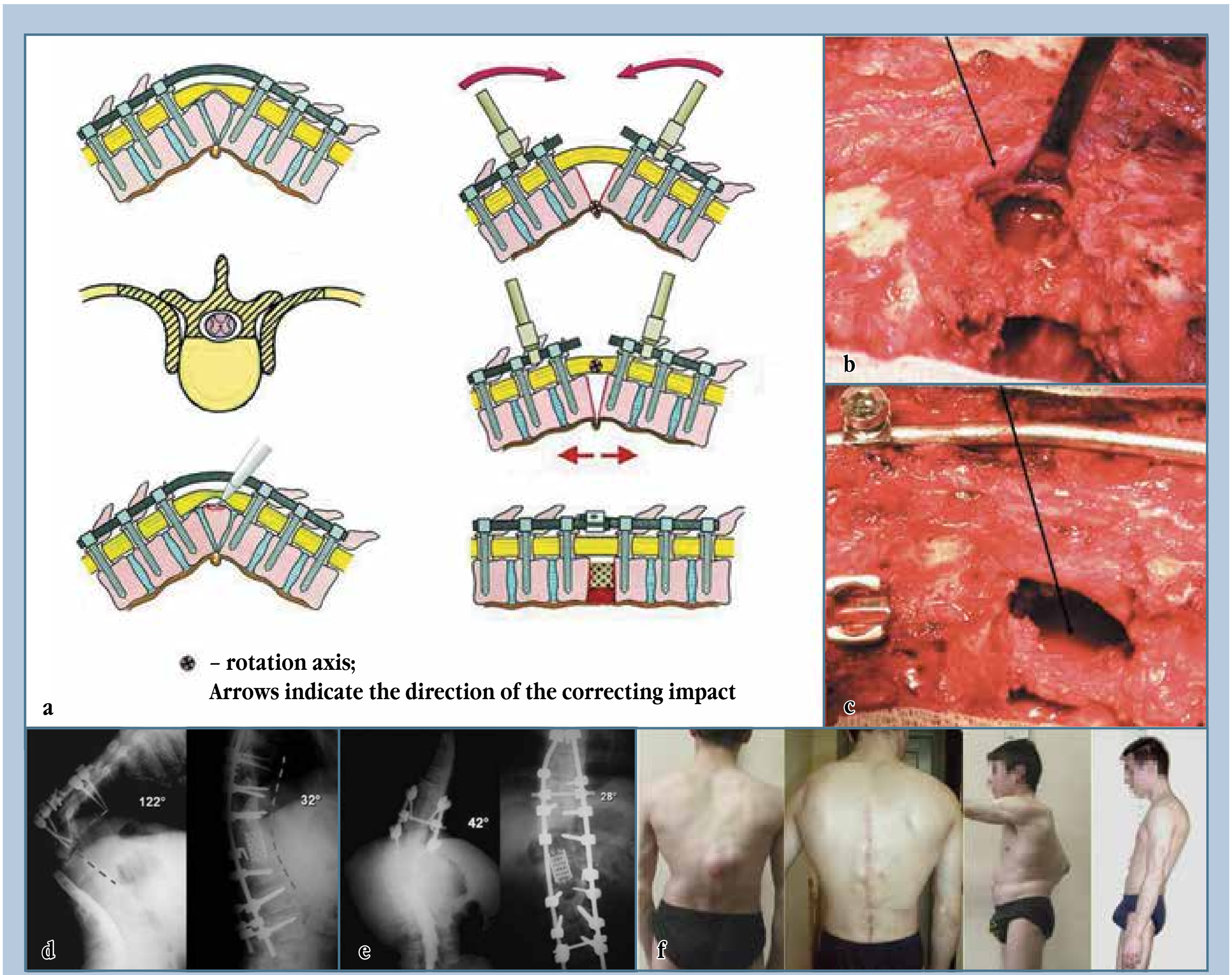

Fig. 6
Information on 17-year-old patient S. with postlaminectomic kyphosis: **a** – scheme of operation procedure by N. Kawahara et al. [6]; **b** – operative wound: decompression of spinal canal; **c** – operative wound after corporectomy; **d** – lateral radiograms before and after surgery: correction of the kyphotic deformity from 122° to 32°, physiological sagittal spine profile has been formed; **e** – frontal radiograms before and after surgery: frontal correction of the deformity from 422° to 28° (14°;33.3 %); **f** – the patient's appearance before and after surgery

sive screening of candidate patients with allowance for their performance status. The problem concerning the proper degree of kyphotic deformity correction deserves special attention, since hypercorrection may cause secondary disorders of spinal sagittal balance associated with flattening of lumbar lordosis, resulting in development and progression of degenerative changes not only in the adjacent spinal portions but in lower limb joints as well [10].

Conclusion

Extension, mobility, deformity localization, and the relative area of spinal canal stenosis, along with presence of neuropathic deficit, its intensity and duration, are the main criteria for choice of the strategy for surgical treatment of extended kyphosis.

Application of corrective vertebrectomy dramatically enhances the efficiency of intraoperative correction of kyphotic deformities. Three-column vertebrectomy is indicated for patients with severe rigid kyphotic deformities (long-standing posttraumatic, iatrogenic, and congenital deformities after the completion of spinal growth).

It is reasonable to use two-stage surgery to ensure efficient correction of severe dysplastic and neurogenic kyphotic deformities. The surgery consists of multilevel discectomy at the deformity apex, preliminary correction in a halo-pelvic traction system, and further dorsal correction and fixation with polysegmental instrumentation. Smith-Petersen posterior corrective osteotomy is indicated for patients with Scheuermann's rigid kyphosis and neurogenic kyphotic deformities with bone or bone-fibrosis fusion of dorsal spinal elements.

Thus, the differential approach to surgical treatment of extended kyphotic deformities of the thoracic and lumbar spine allows a surgeon to enhance efficiency of surgical correction of kyphotic deformity, to reduce the risk of development or progression of neurological disorders, and to restore the support function of the spine. It also promotes formation of normal sagittal spine profile and elimination of cosmetic defects.

References

1. **Borisov AK.** [Surgical treatment of fractures of thoracic and lumbar spine with transpedicular fixation]. Candidate of Medicine Thesis. Moscow, 2001. In Russian.
2. **Kuleshov AA.** [Severe types of scoliosis. Surgical treatment and functional details of some organs and systems]. Doctor of Medicine Thesis. Moscow, 2007. In Russian.
3. **Mikhailovsky MV., Fomichev NG.** [Surgical Treatment of Spine Deformities]. Novosibirsk, 2002. In Russian.
4. **Movshovich IA.** [Orthopedic Surgery. Doctors' Manual]. Moscow, 1994. In Russian.
5. **Mushkin AY.** [Surgical correction of nonsystemic angle kyphosis in children (tuberculous spondylitis, congenital defects of vertebrae)]. Summary of the Doctor of Medicine Thesis. St. Petersburg, 2000. In Russian.
6. **Ulrikh EV, Mushkin AY.** [Vertebrology in Terms, Numbers, and Figures]. St. Petersburg, 2001. In Russian.
7. **Tsivian YL.** [Surgical Treatment of Humps]. Moscow, 1973. In Russian.
8. **Chaklin VD., Abalmasova EA.** [Skolisis and Kyphoses]. Moscow, 1973. In Russian.
9. **Boseker EH, Moe JH, Winter RB, et al.** [Determination of "normal" thoracic kyphosis: a roentgenographic study of 121 "normal" children] J. Pediatr. Orthop. 2000; (20): 796–798.
10. **Bridwell KH, Lewis SJ, Rinella A, et al.** [Pedicle subtraction osteotomy for the treatment of fixed sagittal imbalance. Surgical technique]. J. Bone Joint Surg. Am. 2004; (86. Suppl.1): 44–50.
11. **Costanzo G, Cellocco P, Di Francesco A, et al.** [The role of JOA score as an indication for surgical or conservative treatment of symptomatic degenerative lumbar spinal stenosis]. J. Orthop. Traumatol. 2005;(6): 150–153.
12. **Denis F, Armstrong GW, Searls K, et al.** [Acute thoracolumbar burst fractures in the absence of neurologic deficit. A comparison between operative and nonoperative treatment]. Clin. Orthop. Relat. Res. 1984. (189): 142–149.
13. **Frankel HL, Hancock DO, Hyslop G.** [The value of postural reduction in the initial management of closed injuries of the spine with paraplegia and tetraplegia]. Paraplegia. 1969; (7):179–192.
14. **Hosman AJ, Langeloo DD, de Kleuver M, et al.** [Analysis of the sagittal plane after surgical management for Scheuermann's disease: a view on overcorrection and the use of an anterior release]. Spine. 2002; (27):167–175.
15. **Johnston CE, Elerson E, Dagher G.** [Correction of adolescent hyperkyphosis with posterior-only threaded rod compression instrumentation: is anterior spinal fusion still necessary?] Spine. 2005; (30): 1528–1534.
16. **Kawahara N, Tomita K, Baba H, et al.** [Closing-opening wedge osteotomy to correct angular kyphotic deformity by a single posterior approach]. Spine. 2001; (26):391–402.
17. **Kim YJ, Otsuka NY, Flynn JM, et al.** [Surgical treatment of congenital kyphosis] Spine. 2001; (26): 2251–2257.
18. **Lonstein JE, Winter RB, Moe JH, et al.** [Neurologic deficits secondary to spinal deformity. A review of the literature and report of 43 cases]. Spine. 1980; (5):331–355.
19. **McMaster MJ, Singh H.** [The surgical management of congenital kyphosis and kyphoscoliosis]. Spine. 2001; (26):2146–2155.
20. **Smith JT, Gollogly S, Dunn HK.** [Simultaneous anterior-posterior approach through a costotransversectomy for the treatment of congenital kyphosis and acquired kyphoscoliotic deformities]. J. Bone Joint Surg. Am. 2005; (87): 2281–2289.
21. **Yucesoy K, Crawford NR.** [Increase in spinal canal area after inverse laminoplasty: an anatomical study]. Spine. 2000; (25):2771–2776.

Corresponding author:
Alexander Kuleshov, Marchel Vetrila
N.N. Priorov Central Institute of
Traumatology and Orthopedics
ul. Priorova 10, Moscow, 127299 Russia
cito-spine@mail.ru

Received March 16, 2009